

# The Continuity of the Body: Hypothesis of Treatment of the Five Diaphragms

Bruno Bordoni, DO, PhD,<sup>1,2</sup> and Emiliano Zanier, DO, PhD<sup>2</sup>

## Abstract

The diaphragm muscle should not be seen as a segment but as part of a body system. This muscle is an important crossroads of information for the entire body, from the trigeminal system to the pelvic floor, passing from thoracic diaphragm to the floor of the mouth: the network of breath. Viola Frymann first spoke of the treatment of three diaphragms, and more recently four diaphragms have been discussed. Current scientific knowledge has led to discussion of the manual treatment of five diaphragms. This article highlights the anatomic connections and fascial and neurologic aspects of the diaphragm muscle, with four other structures considered as diaphragms: that is, the five diaphragms. The logic of the manual treatment proposed here is based on a concept and diagnostic work that should be the basis for any area of the body: The patient never just has a localized symptom but rather a system that adapts to a question.

## Introduction: Anatomy and Fascial and Neurologic Connections of The Five Diaphragms

**V**IOLA FRYMANN FIRST SPOKE OF the treatment of three diaphragms<sup>1</sup> and only recently started talking about four diaphragms.<sup>2</sup> Current scientific knowledge allows discussion of manual treatment of five diaphragms: the diaphragm muscle, pelvic floor, floor of the mouth, thoracic outlet, and tentorium of the cerebellum. Previous work has shown the connections between all these structures, with links to fascial and neurologic continuity.<sup>3</sup>

This article addresses the anatomic continuity of the respiratory diaphragm to validate the proposed manual treatment.

During correct respiration, coughing, or any other diaphragmatic physiologic alteration, a symmetric change in the pelvic floor can be observed.<sup>4</sup> For instance, if during inhalation the main inspiratory muscle descends, there will be a corresponding lowering of the pelvic floor.<sup>4</sup> This process has been verified with real-time magnetic resonance imaging of living persons, and one of its aims is controlling—and responding to—any change in intra-abdominal pressure, for example.<sup>4</sup> However, it also ensures the steadiness of the human trunk and, obviously, preserves continence during respiration and coughing.<sup>4</sup> Various studies prove that, before an act of inhalation, electrical activity of the muscles of the pelvic floor can be observed;<sup>4</sup> the same electrical activity is traceable for the musculus transversus and the musculus

obliquus internus.<sup>4</sup> The pelvic diaphragm not only plays an important role in supporting the pelvic organs and in resisting increasing pressure but also affects the correct functionality of respiration.<sup>4</sup> The retroambiguus nucleus—which is an important monitoring center for phrenic medullary areas and is housed in the medulla oblongata or so-called bulb—controls the abdominal muscles as well.<sup>5,6</sup> This means that respiration must be supported by the pelvic floor in order to properly control the pressure of intra-abdominal liquid. These same areas, which are connected to the motoneurons of the mouth floor, probably send the premotor order to the pelvic zone.<sup>3</sup>

The phrenic nerve innervates the diaphragm and runs from the roots of C3–C5;<sup>7</sup> the phrenic neurons are housed in lamina IX of the ventral horn in the cervical spinal cord and receive information via presynaptic contacts in the medulla.<sup>8</sup> According to some authors, the path of the phrenic nerve involves the entire brachial plexus and the entire cervical plexus (C1–T1).<sup>9</sup> Along its pathway, the phrenic nerve anastomoses with the nervus subclavius, which innervates the musculus subclavius, specifically the first rib and the clavicle (C5–C6).<sup>9</sup> Therefore, if there is a phrenic disorder, it is possible to contract the subclavius, raising the first rib and reproducing a thoracic outlet syndrome, with the relevant symptoms.<sup>10,11</sup> For example, pressure on C8–T1 can cause problems in the little finger.<sup>12</sup> The scalene muscles, which are innervated by the cervical and brachial plexuses, are equally important.<sup>13</sup> It is worth emphasizing that a

<sup>1</sup>Don Carlo Gnocchi IRCCS, Department of Cardiology, IRCCS S. Maria Nascente, Don Carlo Gnocchi Foundation, Milano, Italy.

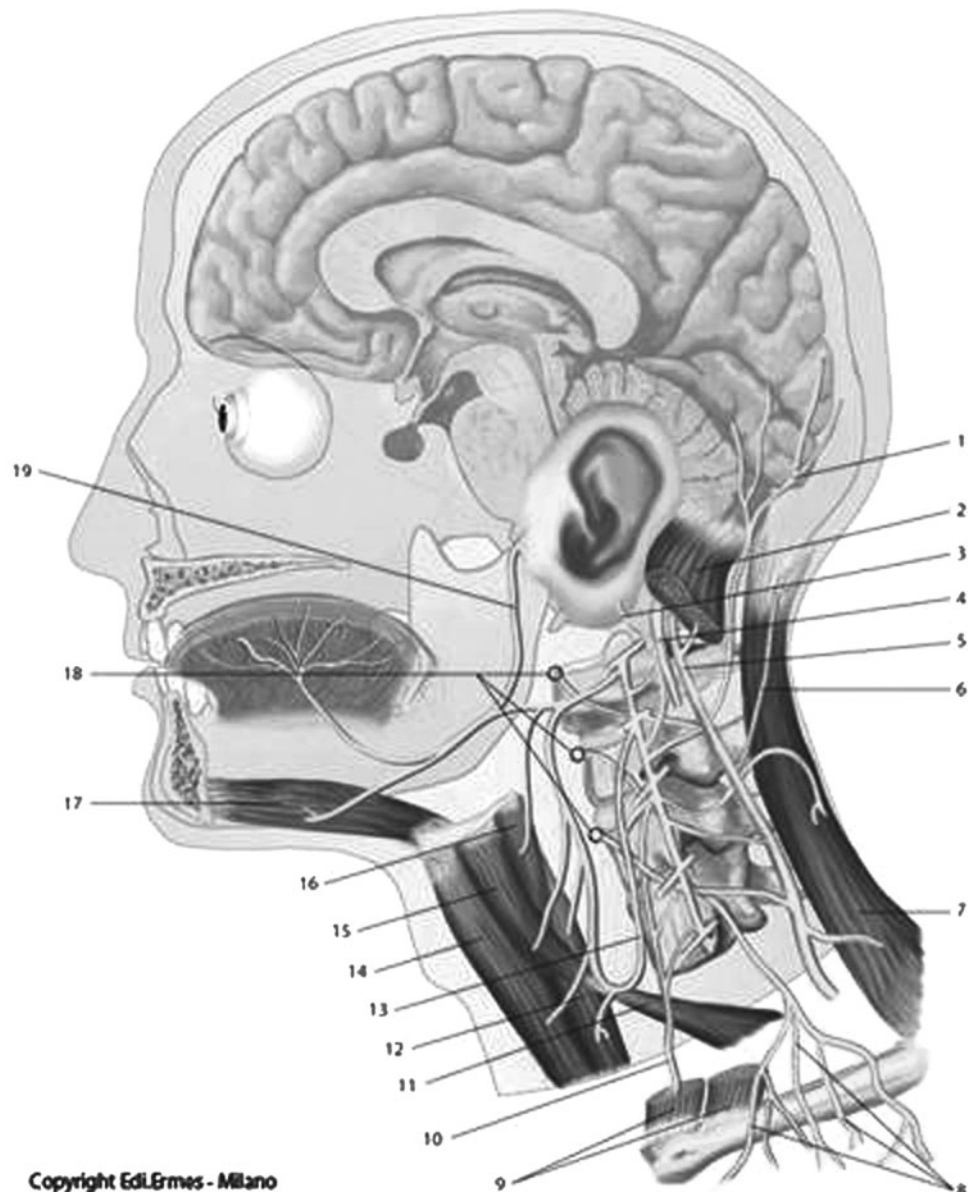
<sup>2</sup>School CRESO, Osteopathic Centre for Research and Studies, Falconara Marittima (Ancona) and Castellanza (Varese), Italy.

brachial disorder can provoke phrenic and diaphragmatic disorders.<sup>14</sup> The same occurs for any other anatomic connection. Moreover, the phrenic nerve meets the stellate ganglion (and indirectly the cardiac ganglion), which is located above the first rib and generated from the unification of the median ganglion and the inferior cervical ganglion;<sup>13,15-17</sup> this means that a disorder of the former or of the latter could produce symptoms in the complete cervical tract. There is a close link between the diaphragm and the thoracic outlet.

With reference to neurology, the phrenic nerve along its pathway anastomoses with the vagus, while the vagus runs through the crural region of the diaphragm, innervating it.<sup>13,18,19</sup> The vagus is joined to the medial longitudinal fasciculus by afferent and efferent connections; moreover, it is in contact with the spinal trigeminal nucleus by afferent connections.<sup>13,19,20,21</sup> This means that diaphragmatic dysfunction produces symptoms that are observable in the re-

gion of the cervical base, in the mouth floor, and in the dura, as well as in the eyes. It is important to proceed in order. The medial longitudinal fasciculus is composed of fibers that connect the mesencephalon and most cranial nerves, such as the trigeminal nerve (V) and the cranial nerves that innervate the eye (II, III, IV, the first division of cranial nerve V, and VI), the tongue (the hypoglossal nerve, XII), and the cervical base (C1-C3).<sup>21-24</sup> Therefore, the medial longitudinal fasciculus is an important path of connection whose margins go from the mesencephalon-diencephalon to the lumbar spinal cord (L4) and farther, at least according to some sources.<sup>21,25</sup> With reference to the neurologic connections, the nerve of Arnold or C2 enters the cranium (probably via the vagus or the hypoglossal nerve), where it innervates the inferior region of the tentorium cerebelli or tentorial diaphragm.<sup>20</sup> In contrast, the superior area of the tentorium cerebelli is innervated by the nervus recurrens (of Arnold), which is a stem of the first branch of the trigeminal

**FIG. 1.** The cervico-cranial area. 1, occipital nerve or c2; 19, XII cranial nerve; 4, cranial nerve; 5, cranial nerve XI; 17, geniohyoid muscle; 10, phrenic nerve. Reproduced with permission from *Anatomia Dell'uomo*, 4th ed. 2010, Milan, Italy: Edi.Ermes.



nerve connected to the eye.<sup>20</sup> The reciprocal tension membranes are innervated by the trigeminal system and, according to recent reports, also by vagus nerve and by hypoglossal nerve.<sup>20</sup>

In regular respiration, the genioglossus and other muscles of the mouth floor, such as the hyoglossus, are electrically involved in coordination with the diaphragm, in a period of time that briefly precedes the contraction of the diaphragm itself.<sup>26,27</sup> The genioglossus moves during the respiratory cycle; during expiration, the muscle moves posteriorly, and during inspiration, it moves anteriorly.<sup>28</sup> Their action assists in ventilation. The greater the inhalation phase in terms of rhythm, the greater the electrical response of these mouth contractile areas.<sup>29</sup> This means that the signals of the peripheral neurons combine with orders from the central nervous system.<sup>29,30</sup> As has recently been proven, in case of respiratory problems of any nature this carefully coordinated relationship can be interrupted, with consequential problems in mastication, deglutition, and respiration (Fig. 1).<sup>31-33</sup> It should be noted close relationship between the diaphragm, the buccal diaphragm, and the dura mater.<sup>9</sup>

The fascial system is also involved: that is, the series of layers of connective tissue that connects the diaphragm to the whole body. The fascia transversalis is the continuation of the endothoracic fascia and is related to the diaphragm.<sup>34</sup> It originates in the deep and median cervical fascia (i.e., the neck, including the scalene muscles and the phrenic nerve), and goes to the occipital pharyngeal tubercle, where the dura and the membranes that stand in mutual tension communicate.<sup>35,36</sup> Therefore, the deep cervical fascia reaches the pubis via the fascia transversalis.<sup>36</sup> This fascia covers the epimysium of the transversus abdominis muscle, then arrives at the linea alba of the rectus abdominis, and reaches the inguinal and pubic regions.<sup>37</sup> It is important to remember that the transversus abdominis muscle, along with the respiratory diaphragm and the pelvic floor, plays a significant role in sacroiliac steadiness.<sup>35,38,39</sup>

Another important fascial system is the thoracolumbar fascia, which develops posteriorly, from the sacral region, through the thoracic region, and finally to the cervical region.<sup>40</sup> It involves muscles such as the latissimus dorsi, the trapezius, the gluteus maximus, and the external oblique, as well as the ligaments that connect the ileum to the sacrum (the sacral bone belongs to the system of the pelvic floor).<sup>40,41</sup> The medial and lateral arcuate ligaments of the diaphragm muscle act as a bridge between the thoracolumbar fascia posteriorly and the transversalis fascia anteriorly.<sup>34,37,42</sup>

### Manual Treatment of the Five Diaphragms

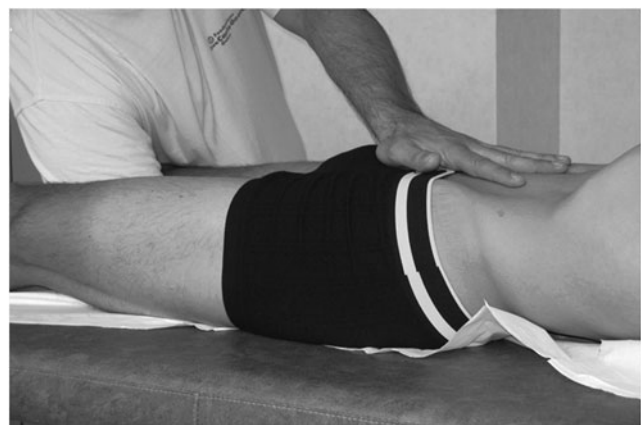
It is important to remember that, as happens for many methods of treatment, whether manual or otherwise, scientific proof is not available for every existing treatment. This does not mean that, in absence of scientific evidence, something is not valid; if that were the case there would be no treatments or any improvement in rehabilitative practice. The operator is more important than the technique, but the good operator knows good techniques.

Manual treatment is useful in most cases of disease, systemic and local, where there is always an alteration of the function and position of the diaphragm. The treatment mo-

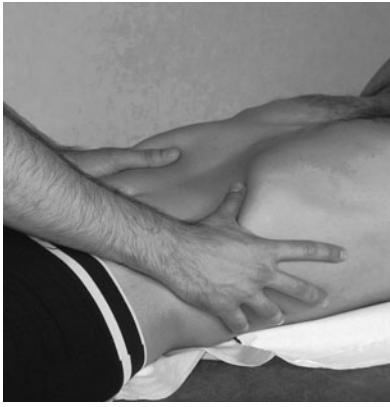dality focuses on the operator's manual skills. Many techniques are available, both for treating the diaphragm directly and for treating the body districts previously discussed here (i.e., the thoracic outlet, the buccal diaphragm, the tentorial diaphragm, and the muscles of the pelvic floor). After accurate examination of these areas, it is important to choose the most appropriate rehabilitative manual approach. This paper suggests some corrective procedures that aim to coordinate all the previously mentioned body structures as much as possible. The objective is to relieve symptoms and to obtain a higher percentage of satisfactory functional recovery, always depending on the patient's particular condition. In fact, even if the techniques here proposed should not completely resolve the problem (e.g., an evident and pathologic alteration of the diaphragm) thanks to the previously mentioned connections, these stimuli can improve the general symptomatologic picture, releasing any anomalous tension due to an incorrect current physiology. To make some examples, in case of chronic congestive heart failure and stroke, the diaphragm is positioned in elevation.<sup>43,44</sup> This means that a reduction of the tensions, by manually inhibiting or balancing them, results in the prominence of the preserved functionality and reduced symptoms.<sup>45</sup>

Generally, the diaphragm has a greater excursion in a supine position because it is not engaged in postural control; this results in a higher recorded lung volume.<sup>46</sup> On the contrary, with sitting or standing, the diaphragmatic expansion is reduced because it is involved in controlling posture.<sup>47</sup> The right portion usually has a greater power of movement.<sup>48</sup> The excursion range of the diaphragm in a physiologic or relaxing state is about 1.5 cm, whereas during forced inhalation it reaches up to 6–10 cm.<sup>3</sup>

The strategy suggested here (just one among many) consists of initial treatment of the pelvic floor, moving up to the diaphragm, the thoracic outlet, the mouth floor, and, finally, the tentorium cerebelli. Figures 2–6 show several manual techniques recommended for different body districts. They



**FIG. 2.** Treatment of the pelvic floor. With the patient supine, place one hand under the sacral bone and the other on the pubis, with fingers turned upward, toward the face. When the patient inhales, carefully help the sacral bone rise, while at the same time helping the pubic bone to descend. During exhalation, perform the process in reverse order, until the previous tensions disappear. This therapeutic approach was first proposed by Dr. J.E. Upledger.

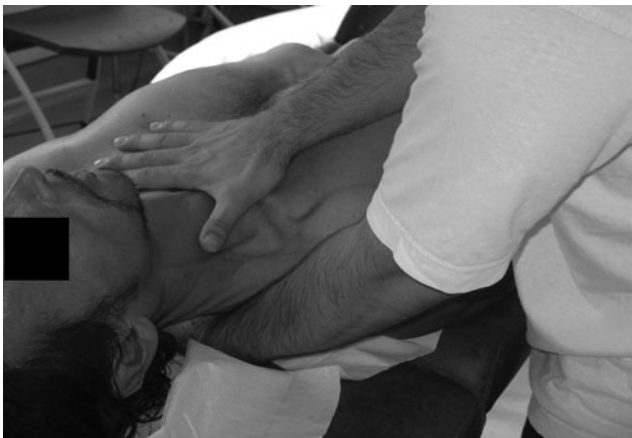

**FIG. 3.** Treatment of the diaphragm. Place your thumbs and the whole tenar side under the diaphragm, in anterolateral position. The purpose is to search for a tensional balance between the right and left hemcupula, hindering or supporting the different tensions previously observed. Remove hands once an equal, slight tension on both sides can be perceived.

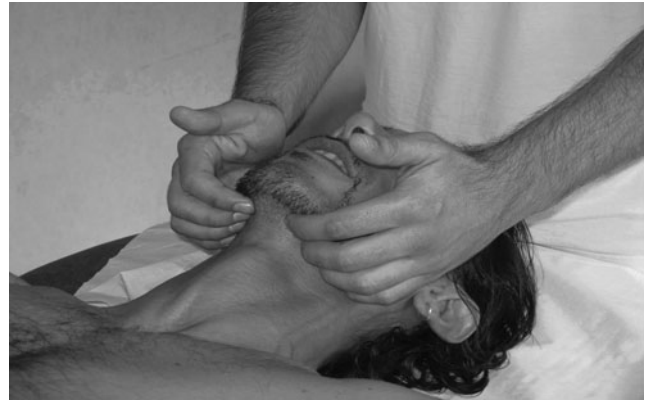should be used after examination of the aforementioned districts with a general, nonspecific, but nevertheless accurate, attention. Emphasis is given to the techniques of Dr. Upledger, which are simple and easily executable.<sup>49,50</sup> Finally, note that the anatomic features described in books do not always correspond to the subjective anatomic appearance, and the palpation of the operator plays an important role in treatment.<sup>51</sup>

### Conclusion

The diaphragm muscle should not be seen as a segment but as part of a body system. To find the correct treatment solutions, one must see the whole and all the links as highlighted in this article. With all these connections, the

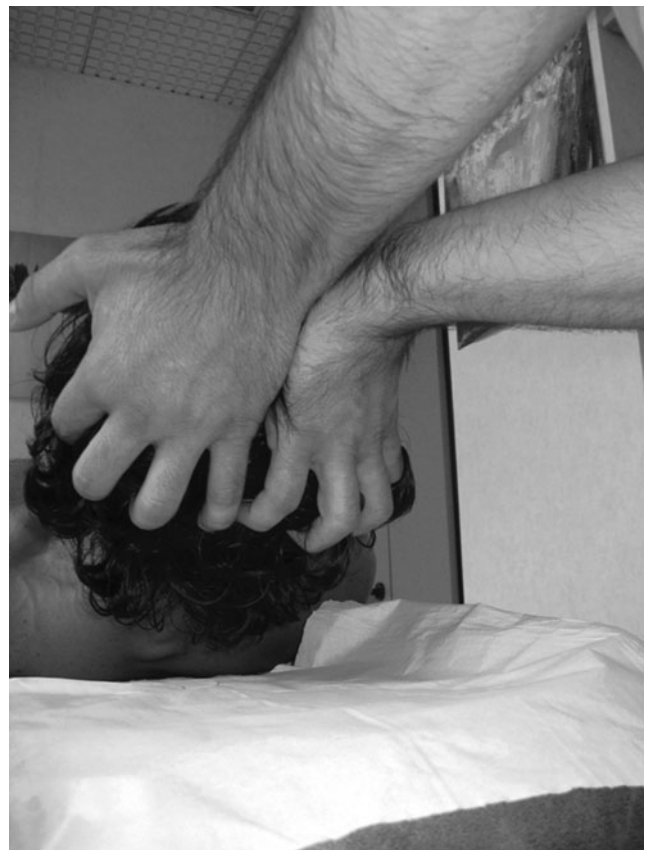

**FIG. 4.** Treatment of the thoracic outlet. Place one hand, with a delicate touch, on the contact point between the two clavicles, and place the other hand under the back, in parallel position. Apply a slight pressure until your hand perceives a release of the tissues, as if there were no resistance in trying to make your hands meet. This therapeutic approach was first proposed by Dr. J.E. Upledger.



**FIG. 5.** Treatment of the floor of the mouth. Place your fingertips in a medial position to the jawline and apply uniform pressure on both sides to balance the existing muscular tensions. Stop when your fingers perceive that the tissue has softened.

symptoms can also occur in areas far from the source of the problem, and work with this manual approach can help achieve a higher success rate. It is hoped that this article contributes to the overall view of the patient and spurred new thinking.



**FIG. 6.** Treatment of the tentorium cerebelli. Place your fingers in a semicircle. Your little fingers go from the external occipital protuberance to the area above the ears so as to indirectly relax the tentorium cerebelli. This therapeutic approach stops when your fingers perceive that the tissue has softened and when the patient experiences less irritation while leaning his or her head.

### Acknowledgments

The authors would like to thank their families for their constant and unfailing support.

### Author Disclosure Statement

No competing financial interests exist.

### References

- Frymann V. The core-link and the three diaphragms. In: Academy of Applied Osteopathy Yearbook 1968. Indianapolis, IN: Academy of Applied Osteopathy, 1968.
- Speece CA, Crow WT. Ligamentous Articular Strain: Osteopathic Manipulative Techniques for the Body. Seattle, WA: Eastland Press, 2001:93,146–147, 161–168.
- Bordoni B, Zanier E. The anatomical connections of the diaphragm: the influence of respiration in the body system. *J Multidiscip Healthc* 2013;6:281–291.
- Talasz H, Kremser C, Kofler M, Kalchschmid E, Lechleitner M, Rudisch A. Phase-locked parallel movement of diaphragm and pelvic floor during breathing and coughing—a dynamic MRI investigation in healthy females. *Int Urogynecol J* 2011;22:61–68.
- Mantilla CB, Sieck GC. Phrenic motor unit recruitment during ventilatory and non-ventilatory behaviors. *Respir Physiol Neurobiol* 2011;179:57–63.
- Boers J, Ford TW, Holstege G, Kirkwood PA. Functional heterogeneity among neurons in the nucleus retroambiguus with lumbosacral projections in female cats. *J Neurophysiol* 2005;94:2617–2629.
- Nicaise C, Hala TJ, Frank DM, et al. Phrenic motor neuron degeneration compromises phrenic axonal circuitry and diaphragm activity in a unilateral cervical contusion model of spinal cord injury. *Exp Neurol* 2012;235:539–552.
- Jones SE, Saad M, Lewis DI, Subramanian HH, Dutschmann M. The nucleus retroambiguus as possible site for inspiratory rhythm generation caudal to obex. *Respir Physiol Neurobiol* 2012;180:305–310.
- Banneheka S. Morphological study of the ansa cervicalis and the phrenic nerve. *Anat Sci Int* 2008;83:31–44.
- Zhang Z, Dellon AL/ Facial pain and headache associated with brachial plexus compression in the thoracic inlet. *Microsurgery* 2008;28:347–350.
- Laulan J, Fouquet B, Rodaix C, et al. Thoracic outlet syndrome: definition, aetiological factors, diagnosis, management and occupational impact. *J Occup Rehabil* 2011; 21:366–373.
- Ferrante MA. The thoracic outlet syndromes. *Muscle Nerve* 2012;45:780–795.
- Drake R, Vogl AW, Mitchell AWM. *Gray's Anatomy for Students*. 2nd ed. New York: Elsevier-Churchill-Livingstone, 2009.
- Franko OI, Khalpey Z, Gates J. Brachial plexus trauma: the morbidity of hemidiaphragmatic paralysis. *Emerg Med J* 2008;25:614–615.
- Bałkowiec A, Szulczyk P. Properties of postganglionic sympathetic neurons with axons in phrenic nerve. *Respir Physiol Neurobiol* 1992;88:323–331.
- Nozdrachev AD, Fateev MM, Jiménez B, Morales MA. Circuits and projections of cat stellate ganglion. *Arch Med Res* 2003;34:106–115.
- Lachman N, Syed FF, Habib A, et al. Correlative anatomy for the electrophysiologist, part II: cardiac ganglia, phrenic nerve, coronary venous system. *J Cardiovasc Electro-physiol* 2011;22:104–110.
- Pickering M, Jones JF. The diaphragm: two physiological muscles in one. *J Anat* 2002;201:305–312.
- Messlinger K, Fischer MJ, Lennerz JK. Neuropeptide effects in the trigeminal system: pathophysiology and clinical relevance in migraine. *Keio J Med* 2011;60:82–89.
- Kemp WJ 3rd, Tubbs RS, Cohen-Gadol AA. The innervation of the cranial dura mater: neurosurgical case correlates and a review of the literature. *World Neurosurg* 2012;78:505–510.
- Haines DE. *Neuroanatomy. An Atlas of Structures, Sections, and Systems*. 6th ed. Philadelphia: Lippincott Williams & Wilkins, 2004.
- Bae YJ, Kim JH, Choi BS, Jung C, Kim E. Brainstem pathways for horizontal eye movement: pathologic correlation with MR imaging. *Radiographics* 2013;33:47–59.
- Sakaie K, Takahashi M, Dimitrov I, et al. Diffusion tensor imaging the medial longitudinal fasciculus in INO: opportunities and challenges. *Ann N Y Acad Sci* 2011;1233:307–312.
- Zwergal A, Strupp M, Brandt T, Büttner-Ennever JA. Parallel ascending vestibular pathways: anatomical localization and functional specialization. *Ann N Y Acad Sci* 2009;1164:51–59.
- Kushiro K, Bai R, Kitajima N, Sugita-Kitajima A, Uchino Y. Properties and axonal trajectories of posterior semicircular canal nerve-activated vestibulospinal neurons. *Exp Brain Res*. 2008;191:257–264.
- Borel JC, Melo-Silva CA, Gakwaya S, Sériès F. Influence of CO<sub>2</sub> on upper airway muscles and chest wall/diaphragm corticomotor responses assessed by transcranial magnetic stimulation in awake healthy subjects. *J Appl Physiol* 2012;112:798–805.
- Wang W, Similowski T, Sériès F. Interaction between genioglossus and diaphragm responses to transcranial magnetic stimulation in awake humans. *Exp Physiol* 2007;92:739–747.
- Cheng S, Butler JE, Gandevia SC, Bilston LE. Movement of the tongue during normal breathing in awake healthy humans. *J Physiol* 2008;586(Pt 17):4283–4294.
- Rice A, Fuglevand AJ, Laine CM, Fregosi RF. Synchronization of presynaptic input to motor units of tongue, inspiratory intercostal, and diaphragm muscles. *J Neurophysiol* 2011;105: 2330–2336.
- Uysal H, Kizilay F, Unal A, Güngör HA, Ertekin C. The interaction between breathing and swallowing in healthy individuals. *J Electromyogr Kinesiol* 2013;23:659–663.
- Cifra A, Nani F, Nistri A. Respiratory motoneurons and pathological conditions: lessons from hypoglossal motoneurons challenged by excitotoxic or oxidative stress. *Respir Physiol Neurobiol* 2011;179:89–96.
- Grace KP, Hughes SW, Horner RL. Identification of the mechanism mediating genioglossus muscle suppression in REM sleep. *Am J Respir Crit Care Med* 2013;187:311–319.
- Luo YM, Tang J, Jolley C, et al. Distinguishing obstructive from central sleep apnea events: diaphragm electromyogram and esophageal pressure compared. *Chest* 2009;135:1133–1141.
- Skandalakis PN, Zoras O, Skandalakis JE, Mirilas P. Transversalis, endoabdominal, endothoracic fascia: who's who? *Am Surg* 2006;72:16–18.
- Paoletti S. *The Fasciae: Anatomy, Dysfunction and Treatment*. Seattle, WA: Eastland Press, 2006.
- Mihalache G, Indrei A, Tăranu T. The anterolateral structures of the neck and trunk. *Rev Med Chir Soc Med Nat Iasi* 1996;100:69–74.

37. Peiper C, Junge K, Prescher A, Stumpf M, Schumpelick V. Abdominal musculature and the transversalis fascia: an anatomical viewpoint. *Hernia* 2004;8:376–380.
38. O’Sullivan PB, Beales DJ. Changes in pelvic floor and diaphragm kinematics and respiratory patterns in subjects with sacroiliac joint pain following a motor learning intervention: a case series. *Man Ther* 2007;12:209–218.
39. Bø K, Sherburn M. Evaluation of female pelvic-floor muscle function and strength. *Phys Ther* 2005;85:269–282.
40. Willard FH, Vleeming A, Schuenke MD, Danneels L, Schleip R. The thoracolumbar fascia: anatomy, function and clinical considerations. *J Anat* 2012;221:507–536.
41. Soljanik I, Janssen U, May F, et al. Functional interactions between the fossa ischioanalis, levator ani and gluteus maximus muscles of the female pelvic floor: a prospective study in nulliparous women. *Arch Gynecol Obstet* 2012;286:931–938.
42. Loukas M, Shoja MM, Thurston T, et al. Anatomy and biomechanics of the vertebral aponeurosis part of the posterior layer of the thoracolumbar fascia. *Surg Radiol Anat* 2008;30:125–129.
43. Caruana L, Petrie MC, McMurray JJ, MacFarlane NG. Altered diaphragm position and function in patients with chronic heart failure. *Eur J Heart Fail* 2001;3:183–187.
44. Voyvoda N, Yücel C, Karatas G, Oguzülgen I, Oktar S. An evaluation of diaphragmatic movements in hemiplegic patients. *Br J Radiol* 2012;85:411–414.
45. Lancaster DG, Crow WT. Osteopathic manipulative treatment of a 26-year-old woman with Bell’s palsy. *J Am Osteopath Assoc* 2006;106:285–289.
46. Takazakura R, Takahashi M, Nitta N, Murata K. Diaphragmatic motion in the sitting and supine positions: healthy subject study using a vertically open magnetic resonance system. *J Magn Reson Imaging* 2004;19:605–609.
47. Kolar P, Sulc J, Kyncl M, et al. Stabilizing function of the diaphragm: dynamic MRI and synchronized spirometric assessment. *J Appl Physiol* 2010;109:1064–1071.
48. Kolar P, Neuwirth J, Sanda J, et al. Analysis of diaphragm movement during tidal breathing and during its activation while breath holding using MRI synchronized with spirometry. *Physiol Res* 2009;58:383–392.
49. Harrison RE, Page JS. Multipractitioner Upledger craniosacral therapy: descriptive outcome study 2007–2008. *J Altern Complement Med*. 2011;17:13–17.
50. Upledger JE, Vredevoogd JD. *Craniosacral Therapy*. Seattle, WA: Eastland Press; 1983.
51. Bordoni B, Zanier E. Cranial nerves XIII and XIV: nerves in the shadows. *J Multidiscip Healthc* 2013;6:87–89.

Address correspondence to:

*Bruno Bordoni, DO, PhD*

*School CRESO*

*Osteopathic Centre for Research and Studies*

*Via Santorre di Santarosa*

*60015 Falconara Marittima, Ancona*

*Italy*

*E-mail: bordonibruno@hotmail.com*